

Buccal Mucosal Flaps: A Review

Erdem Tezel, M.D.

Istanbul, Turkey

The defects of mucosal surfaces of the face, either congenital, traumatic, or postoperative, have been prominent subjects of plastic surgery. Local skin flaps and free flaps have been used to repair these defects. Because the face is the most vascularized portion of the body, skin flaps in this area have a great chance for viability. Buccal mucosa also shares the same feature of vascularity and thus has the capability of amazingly fast healing. Taking into consideration these features, and the idea of using the most similar tissue for reconstruction, it is easy to understand why plastic surgeons have described many oral mucosal flaps. The purpose of this article is to collate, summarize, and critique the information available on the mucosal flaps. I reviewed the buccal mucosal flaps according to their sites of use.

LIP AND VERMILION RECONSTRUCTION

Lips are a flexible, mobile structure of the face and perform many functions: prehension of solids, prevention of drooling and loss of food during mastication, formation of labial sounds, accomplishment of a sphincteric action that is particularly evident in the newborn, and expression of emotions.¹ The lips are formed by a muscular layer, covered externally by skin and covered internally by "wet" mucous membrane and submucosa. The vermilion constitutes the transitional zone between wet mucosa inside and skin outside.

Images of lips are drawn and sculpted by artists. They are praised in poetry and serve as subjects of songs. Lips are decorated, embellished, and painted with variations in style from culture to culture. Despite any changes performed, it is undeniable that lips, in their natural, unaltered state, are truly objects of fascination and beauty.² Of course, vermilion is one

of the most important parts of the lips, and its reconstruction is an inevitable goal. It is a major challenge for plastic surgeons, especially in wide defects. Vermilion reconstruction is a complementary operation of lip reconstruction. A defect or irregularity of the vermilion spoils the appearance of an otherwise excellently repaired lip.

Various methods have been employed for such wide defects. Schulten³ described a bipedicated flap of the upper lip for reconstruction of missing vermilion of the lower lip. After Schulten, several vermilion flaps were described. The advancement flaps of the neighboring vermilion must be taken into consideration first in small defects.⁴⁻⁷ Vermilion flaps from the opposite lip may be the other alternative. Despite very good results reported,⁸⁻¹⁰ in general, two major shortcomings of these flaps must be mentioned: the operations are in two stages and cause deformity on the opposite vermilion.

The tongue flap was first used for vermilion repair by Lexer¹¹ in 1909. The rich vascularization of the tongue makes use of this flap reliable. However, the operation is a two-stage procedure, and the patient is not comfortable with his or her tongue being attached to the lip while awaiting division. Moreover, these results are not always satisfactory from a cosmetic point of view.

Vestibular mucosa can be advanced in a superoanterior direction to cover the vermilion defect, but the results are not satisfactory. Vermilion becomes thin and the vestibule becomes shallow. This can cause food spillage during eating. The tension-free lip margin is pulled inward and hairs on the lower lip skin cause irritation.¹² To overcome these problems of the vestibular advancement flap, Wilson and

From the Department of Plastic and Reconstructive Surgery, Marmara University School of Medicine. Received for publication February 20, 2001; revised June 5, 2001.

Walker¹³ made a releasing incision at the gingivobuccal sulcus. Thus, it became a bipedicle mucosal flap.

Kolhe and Leonard¹² applied the V-Y advancement procedure to this releasing incision. However, all these were not enough to overcome the previously mentioned problems, and that is why further flap descriptions by several authors were continued. Pelly and Tan¹⁴ used a musculomucosal flap from the buccal aspect of the upper lip for resurfacing the lower lip vermilion defect. This flap was 1×3 cm in size and based on the modiolus.

The amount of excess tissue in the upper lip limits the application of upper lip flaps (either single pedicled or bipediced) for large defects. Rayner and Arscott¹⁵ resurfaced the lower lip vermilion with paired musculomucosal flaps from the cheeks. The flaps were based at the angle of the mouth, and distal ends were just below the parotid duct. The width of the flaps was 1 cm each. Two flaps can cover the whole vermilion by joining in the midline (Fig. 1). The only problem mentioned by the authors was central depression where two flaps were joined and sutured to each other.

The first island mucosal flap was described by Carstens et al.¹⁶ (Fig. 2). They showed in their anatomical study that the musculomucosal flap, based on the facial artery, can be harvested as large as 7×5 cm. It requires meticulous dissection with loupe magnification and may necessitate external nasolabial incision. They reported two lip reconstructions and several oral mucosal defect closures.

One year later, another type of musculomucosal flap with a facial artery pedicle was described¹⁷ (Fig. 3). This flap is planned on the course of facial artery with the help of Doppler ultrasound. Mucosa, submucosa, and a small amount of buccinator muscle are harvested with the facial artery as an axial flap. The pivot point of this flap is on the retromolar trigone,

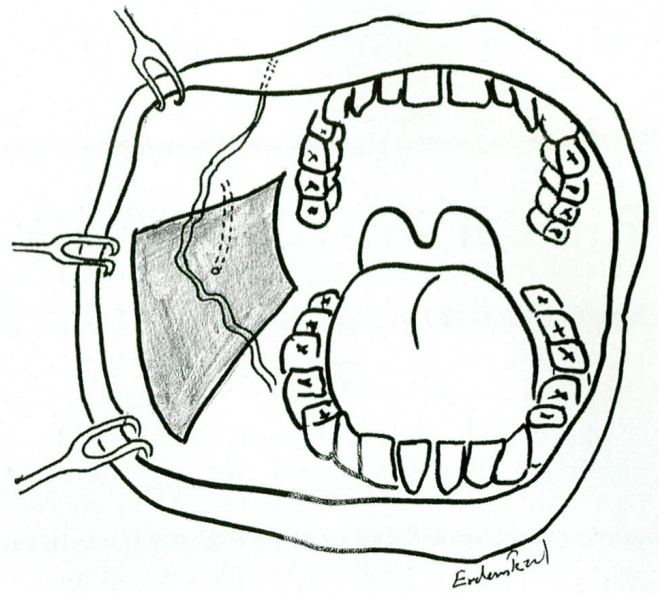


FIG. 2. Island mucosal flap based on the facial artery.

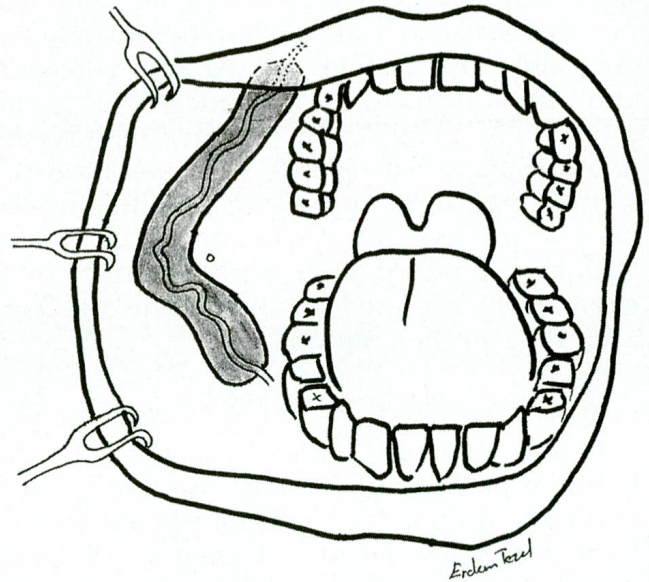


FIG. 3. Musculomucosal flap planned on the course of the facial artery.

and the flap extends to the upper gingivobuccal sulcus. During surgery, care should be taken to ensure that the flap remains axial, with the facial artery running along its entire length, and that there are no twists or constraints on the pedicle. Despite good results presented recently,¹⁸ this is not easy and requires very fine surgical technique and skill.

Ono et al.¹⁹ described a musculomucosal flap pedicled at the angle of the mouth. They included the buccinator muscle for the entire length of the flap. The maximum size of the flap was 1.5×5 cm. After resection of the tumor on the lower lip, they made a supplementary wedge excision and thus diminished

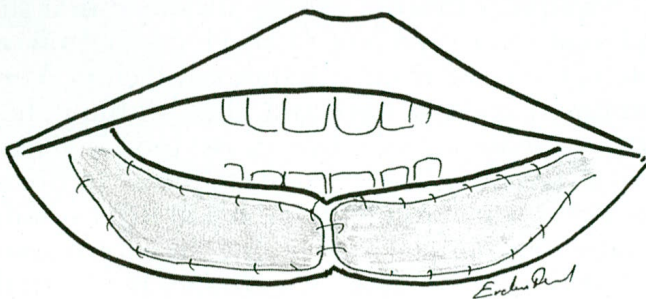


FIG. 1. Rayner and Arscott's flap to cover vermilion. Two flaps join at the midline and lead to the central depression.

the length of the vermilion defect. Then they transposed the musculomucosal flap to the vermilion defect.

Tezel et al.²⁰ described a "commissure-based buccal mucosal flap," which has a random pedicle (Fig. 4). This flap is based at the oral commissure and lies just below the parotid duct opening and extends to the retromolar trigone. A commissure-based buccal mucosal flap consists of mucosa, submucosa, and muscle only under the proximal 1.5 to 2 cm of the flap. Being as large as 3 × 6 cm, the buccal mucosal flap based on the commissure can easily cover an entire vermilion defect by placing the flap from one commissure to the other (Fig. 5). Bilateral commissure-based buccal mucosal flaps were used for lip reconstruction with one of the flaps resurfacing the vermilion defect and the other one covering the inner side of the lip. Because no extra effort is necessary to identify the artery or nerve, it is easy to harvest the flap, and donor morbidity is minimal.

The most important structure when using cheek mucosa as a flap is the orifice of the parotid duct. Care must be taken to spare it. The two important problems when using oral mucosa outside of the mouth are dryness and edema. Dryness and keratotic changes of the mucosal flap are thought to stem from histologic differences between oral mucosa and the vermilion. It may be a cause to increase the edema. Use of moisturizing pomades regularly for a few months helps reduce both problems.

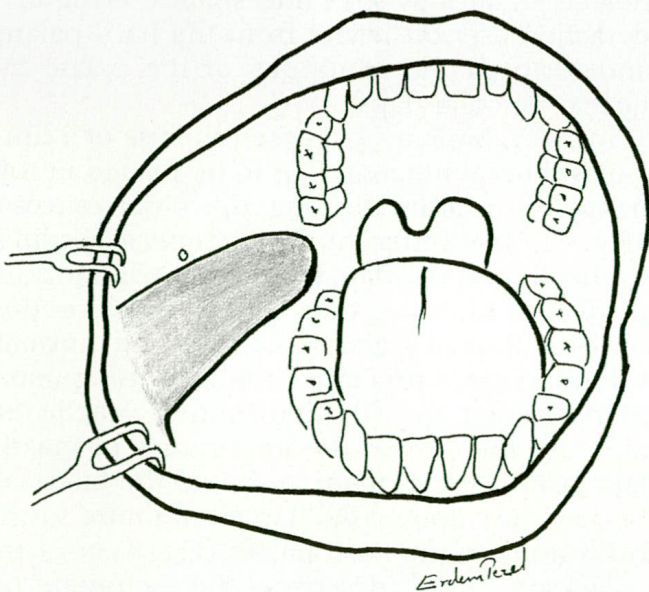


FIG. 4. Commissure-based buccal mucosal flap. This is a random-pedicle flap based at the oral commissure.

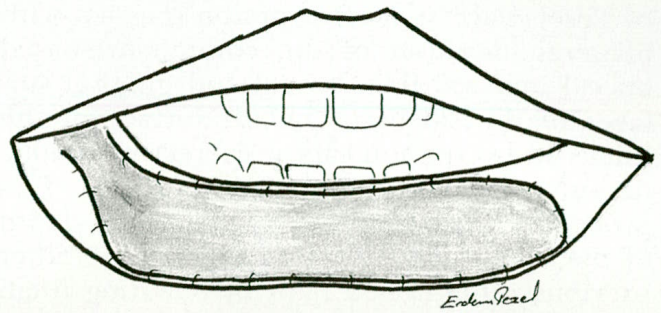


FIG. 5. A commissure-based buccal mucosal flap can cover an entire vermilion defect.

Donor defects of the flaps in cheek mucosa up to 3 cm wide can be closed primarily. The wider donor-site defects can be closed with grafts or be left for secondary healing. Primary closure is always preferable. Because most of the patients who suffer from tumors of the lower lip are elderly, one-stage operations are superior to two-stage procedures, such as cross-lip flaps and tongue flaps.

Several authors described numerous beautiful results with different mucosal flaps; some of them are mentioned above. In deciding on the proper flap, the size of the defect, the age of the patient, the time of the operation, the equipment, and the skill and experience of the surgeon must be weighed.

GINGIVOBUCCAL SULCUS RECONSTRUCTION

Traumatic or postoperative obstruction of the gingivobuccal sulcus restrains lip mobility, causes inward displacement of lip, and limits the use of tooth prostheses. Repair of the gingivobuccal sulcus is one of the most important parts of lip reconstruction. Using skin grafts for sulcus is not only cumbersome, the results are also far from satisfactory. Pressure must be put on the grafts for at least 5 days by special molds that often cause maceration, odor, and discomfort for the patient. Even if the graft takes well, secondary contraction of the graft is a nearly inevitable outcome. Of course, buccal mucosal flaps are superior to grafts for reconstructing the moist mucosa of the sulcus because it consists of similar tissue, with the same texture, color, and moisture. One good alternative is the island mucosal flap described by Carstens et al.¹⁶ The size of the flap provides sufficient mucosal tissue to cover the whole sulcus. The other options are the musculomucosal flap based on the facial artery and the buccal musculomucosal flap of Ono et al.¹⁷⁻¹⁹ The commissure-based buccal mucosal flap described

by Tezel et al.²⁰ is another option (Fig. 4). With bilateral elevation of the commissure-based buccal mucosal flap, buccal and gingival surfaces of the sulcus or buccal surface of the sulcus and vermilion can be corrected simultaneously, as shown in their article (Fig. 6). This procedure easily allows us to create the depth of the sulcus and can be applied to the other previously mentioned flaps by elevating them bilaterally. I believe that reconstruction of the

gingivobuccal sulcus with mucosal flaps provides a far superior result in lip reconstructions for both functional and aesthetic aspects.

PALATAL RECONSTRUCTION

The primary aim of the cleft palate operation is not only to close the cleft but also to produce a long and mobile soft palate, thus achieving physiologic velopharyngeal function. This is necessary for normal speech, natural breathing, and deglutition, and it also prevents middle ear inflammation.

The pushback operation is an effective procedure for velopharyngeal closure, but it does not adequately lengthen the nasal layer. Many methods of palatal repair have been described to permit lengthening of the nasal layer after a pushback procedure. The use of buccal mucosal flaps for lengthening the nasal mucosa was first described by Mukherji.²¹ He used bilateral buccal mucosal flaps based near the anterior pillar of the fauces for both nasal and oral layer closure, either separately or in combination. In his article, he summarized the advantages of the buccal mucosal flaps as an increase in the length of the soft palate of at least 1.5 cm, prevention of the abnormal anatomy of pharyngeal flap operation in a fair number of children with cleft palate, and a decrease in the incidences of perforation at the junction of the soft and hard palates.

Jackson²² utilized local random buccal flaps for closure of secondary palatal fistulas, and concluded that the buccal mucosal flap is invaluable with its extreme flexibility to fit into defects of various sizes and shapes. Ganguli²³ detached the soft palate from the hard palate and restored the continuity of the palate by buccal mucosal flaps.

In 1975, Kaplan²⁴ proposed the use of a unilateral buccal mucosal flap to be turned in for nasal lining after dividing the nasal mucosa (Fig. 7). Two different flap designs according to the base of the flap, retromolar trigone and posterior alveolar buccal sulcus, were described. Kaplan's aim was to achieve normal velopharyngeal function without causing maxillary-alveolar growth deformities. Maeda et al.²⁵ also mentioned the importance of maxillary growth impairment and used the bilateral buccal musculomucosal flap to minimize surgical trauma to the hard palate (Fig. 8).

Jackson et al.²⁶ described the technique of palatal closure that consisted of a transverse division of the nasal layer, insertion of a buccal

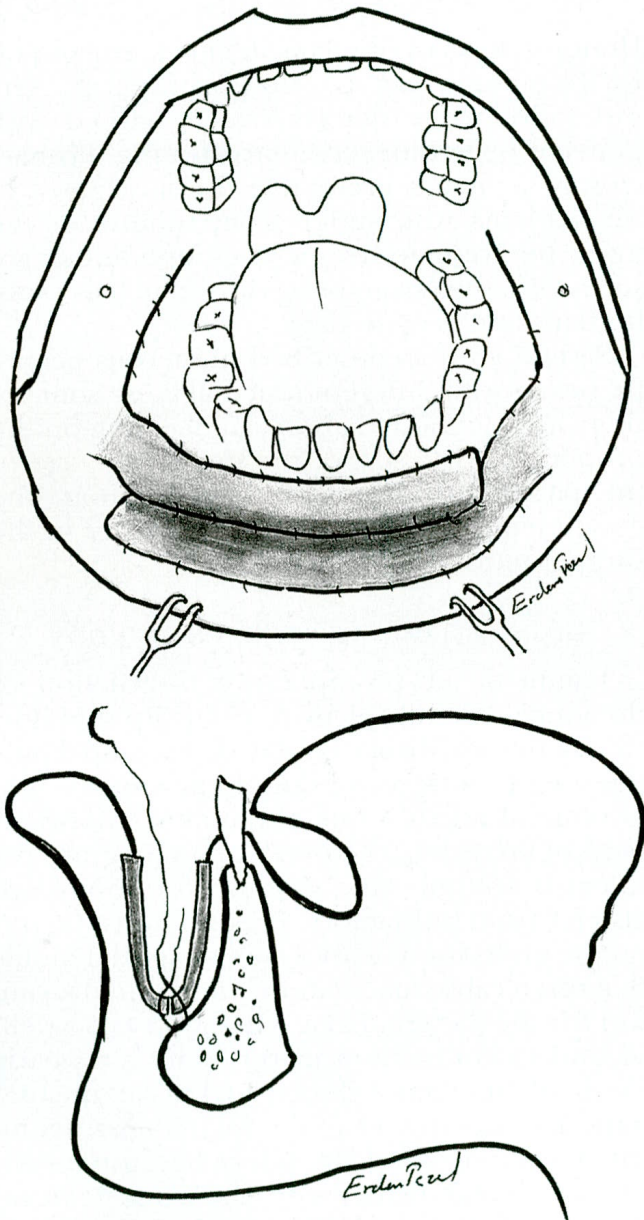


FIG. 6. (Above) Two commissure-based buccal mucosal flaps can be used for gingivobuccal sulcus reconstruction: one of the flaps is used to resurface the gingiva and the contralateral flap is used to cover the inner surface of the lip. (Below) Lateral section of sulcus reconstruction by two commissure-based buccal mucosal flaps. Note that the suture between the two flaps also passes through the periosteum of the mandible to create the depth of the sulcus.

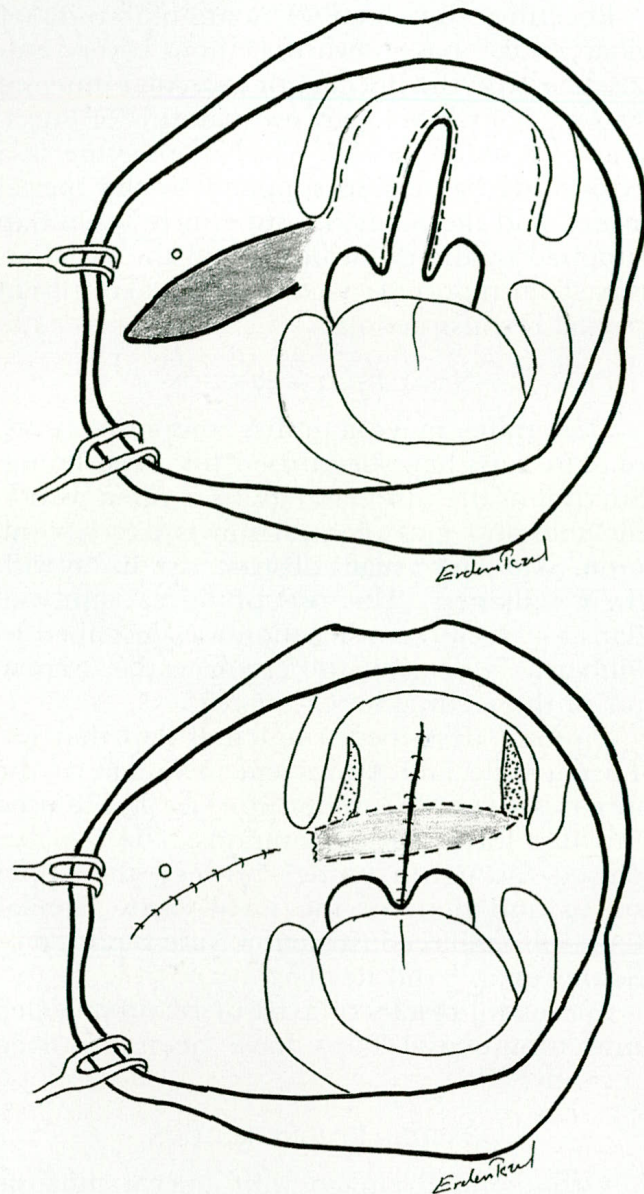


FIG. 7. (Above) Kaplan's buccal mucosal flap for palate reconstruction. (Below) The buccal mucosal flap is turned in for nasal lining, and the donor site is closed primarily.

flap for lengthening, and closure of the oral mucosal layer with Veau flaps without dissection behind the tuberosities and with almost total closure of the lateral donor sites on the palatal shelves. It is stated that with this technique there was minimal scarring in the retro-tuberosity area, which is more important for facial growth than the palatal shelves.

The fate of buccal mucosal flaps in primary palatal repair was reported by Freedlander and Jackson.²⁷ They suggested placing the pedicle of the mucosal flap as far posteriorly as possible, acknowledging that the eruption of the molar might be impeded. In this case, they suggested severing the flap pedicle to expose

the molars. They concluded that buccal mucosal flaps must be reserved for wide clefts.

The first axial buccal musculomucosal flap based on the buccal artery was described by Bozola et al.²⁸ They used a Y-shaped buccal mucosal flap with the buccinator muscle to cover the raw surface of the palate. It is presented in their article that the buccinator musculomucosal flap was not only used for wide cleft palates but also for the treatment of mucosal defects after tumor resection, osteomyelitis of the mandible, and closure of the palatal fistulas.

Nakakita et al.²⁹ modified their technique by using the buccal mucosal flap for oral lining instead of using it for back shift of nasal mucosa. They stated that leaving a raw surface, especially on the soft palate, causes contrac-

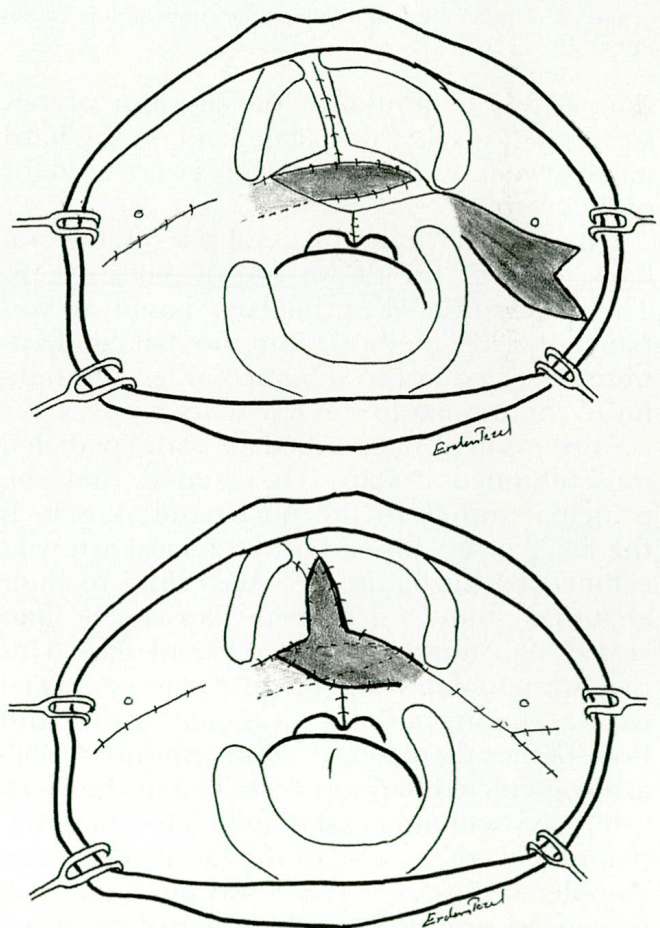


FIG. 8. (Above) Turnover of a buccal musculomucosal flap from one site (on the right side in this drawing) and its transplantation onto the nasal mucosal defect. On the left side, the bilobular musculomucosal flap is planned for oral mucosal covering. (Below) A bilobular musculomucosal flap is rotated to the oral mucosal defect. Thus, one of the mucosal flaps is turned over for the nasal surface covering and the other one (bilobate flap) is rotated to cover the oral mucosal defect.

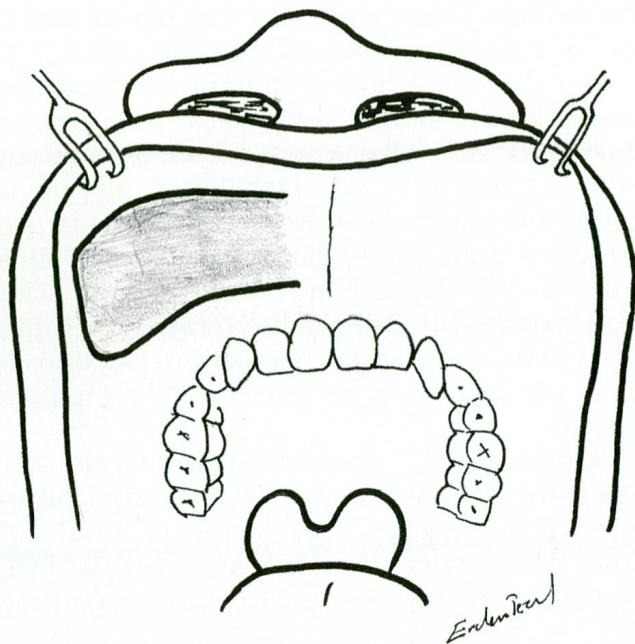


FIG. 9. Tipton's mucosal flap at the inner aspect of the upper lip.

tion. Thus, to minimize the amount of raw surface left on the soft palate, and on the hard palate, two musculomucosal flaps were used for oral covering.

Ohishi et al.³⁰ used bilateral buccal mucosal flaps to cover the donor site of palatal flaps. Their operation was principally based on von Langenbeck's method, but the palatal flaps were dissected at the submucosal level to minimize the trauma to the maxillary bone.

Carstens et al.¹⁶ described an island-pedicled musculomucosal flap. They stated that the principal supply to the buccinator muscle is the facial artery instead of the buccal artery as claimed by Bozola et al.²⁸ According to their anatomic study, a 7 × 5-cm flap can be harvested as a musculomucosal island flap. This flap was used for lip reconstruction, palatal fistula repair, alveolar augmentation, and floor-of-mouth reconstruction. Another facial artery-pedicled flap was described as the facial artery musculomucosal flap.¹⁷ This flap was planned on the course of the facial artery with Doppler ultrasound. It has two pivot point alternatives: superiorly at the gingivobuccal sulcus and inferiorly at the retromolar trigone. They used this flap for reconstruction of the alveolus, nasal septum, lips, floor of mouth, hard palate, and soft palate.

The commissure-based buccal mucosal flap was used to cover the maxillary defects after tumor resection. Bilateral use of this flap can cover a defect as large as 6 × 6 cm.²⁰

Recently, the detailed anatomic study of Zhao et al.³¹ has shown that there is very rich vascularity in the buccinator muscular mucosal system. They developed two patterns of buccinator musculomucosal island flaps. One is a posteriorly based flap supplied by the buccal artery, and the other is a superiorly based flap supplied by the distal portion of the facial artery. They reported successful clinical results of palatal reconstruction.

NASAL RECONSTRUCTION

Skin grafts, mucosa grafts, composite grafts, or skin flaps have been used for nasal lining. Survival of the intranasal grafts is often unpredictable and graft contraction is not uncommon. Skin flaps usually obstruct the airway with their bulkiness. The use of buccal mucosal flaps for nasal reconstruction was described by Filiberti,³² who gives full credit to the originator of the technique, O. Suarez.

Tipton³³ described a mucosal flap that was 1.5 cm wide and 4 to 5 cm in length at the inner aspect of the upper lip (Fig. 9). He used this flap for septal perforations. The flap was passed through a tunnel between the upper sulcus and floor of the nasal cavity. Similar flaps for nasal reconstruction were reported by Soutar et al.³⁴ and Rayner.³⁵

Successful results of axial or island-pedicled musculomucosal flaps have been reported recently.^{17,31}

ORBITAL RECONSTRUCTION

Orbito-oral drainage with buccal mucosal flaps was described by Rayner.³⁵ He used a 1 × 3-cm mucosal flap based near the frenulum of the upper lip. The flap passed through a tunnel from the maxilla up to the orbit. Most of the mucosal flaps described in this article are useful for this purpose. Island pedicle flaps especially have potential for use in socket or lid reconstructions. Successful results of lower lid reconstruction with the island musculomucosal flap are reported by Zhao et al.³¹

Buccal mucosal flaps have several advantages, and they are extremely flexible and available in adequate amounts. Several pedicle alternatives, either random or axial, increase the choices of buccal mucosal flaps according to defects. Flaps easily fit into defects of various sizes and shapes because of their flexibility, and the flaps blend well with surrounding mucosa. In most techniques, the donor sites are closed primarily, without causing deformity or

visible scars. However, in large flaps donor sites need to be grafted. Otherwise, the raw surfaces will be left to heal by secondary intention and may lead to cheek scarring that can limit mouth opening.

Erdem Tezel, M.D.
Cezmi Or Sok 8/1 Emek Ap
81030 Ciftehavuzlar
Istanbul, Turkey

ACKNOWLEDGMENTS

I would like to thank Drs. Ian T. Jackson and Michael Schenden for their valuable help in preparation of this article.

REFERENCES

- Mazzola, R. F., and Lupo, G. Evolving concepts in lip reconstruction. *Clin. Plast. Surg.* 11: 583, 1984.
- Romm, S. On the beauty of lips. *Clin. Plast. Surg.* 11: 571, 1984.
- Schulthen, M. W. En method att erstta en defekt af ena läppen medelst en bryggformad lamba fran den andra. *Finska Läk-Sällsk-Hande.* 35: 859, 1894.
- Goldstein, M. H. A tissue-expanding vermilion myocutaneous flap for lip repair. *Plast. Reconstr. Surg.* 73: 768, 1984.
- Ohtsuka, H., and Nakaoka, H. Bilateral vermilion flaps for lower lip repair. *Plast. Reconstr. Surg.* 85: 453, 1990.
- Sakai, S., Soeda, S., and Terayama, I. Bilateral island vermilion flaps for vermilion reconstruction. *Ann. Plast. Surg.* 20: 460, 1998.
- Iwahira, Y., Yataka, M., and Maruyama, Y. The sliding door flap for repair of vermilion defects. *Ann. Plast. Surg.* 41: 300, 1998.
- Kawamoto, H. K., Jr. Correction of major defects of the vermilion with a cross-lip vermilion flap. *Plast. Reconstr. Surg.* 64: 315, 1979.
- Standoli, L. Cross lip flap in vermilion reconstruction. *Ann. Plast. Surg.* 32: 214, 1994.
- Vega, J. B., Oziel, M., Jackson, I. T., and Sharma, R. K. A new design of a cross-lip vermilion flap. *Ann. Plast. Surg.* 36: 197, 1996.
- Lexer, E. Wangenplastik. *Dtsch. Z. Chir.* 100: 206, 1909.
- Kolhe, P. S., and Leonard, A. G. Reconstruction of the vermilion after "lip-shave." *Br. J. Plast. Surg.* 41: 68, 1988.
- Wilson, J. S. P., and Walker, E. P. Reconstruction of the lower lip. *Head Neck Surg.* 4: 29, 1981.
- Pelly, A. D., and Tan, E. P. Lower lip reconstruction. *Br. J. Plast. Surg.* 34: 83, 1981.
- Rayner, C. R., and Arscott, G. D. A new method of resurfacing the lip. *Br. J. Plast. Surg.* 40: 454, 1987.
- Carstens, M. H., Stofman, G. M., Hurwitz, D. J., et al. The buccinator myomucosal island pedicle flap: Anatomic study and case report. *Plast. Reconstr. Surg.* 88: 39, 1991.
- Pribaz, J., Stephens, W., Crespo, L., and Gifford, G. A new intraoral flap: Facial artery musculomucosal (FAMM) flap. *Plast. Reconstr. Surg.* 90: 421, 1992.
- Pribaz, J. J., Meara, J. G., Wright, S., Smith, J. D., Stephens, W., and Breuing, K. H. Lip and vermilion reconstruction with the facial artery musculomucosal flap. *Plast. Reconstr. Surg.* 105: 864, 2000.
- Ono, I., Gunji, H., Tateshita, T., and Sanbe, N. Reconstruction of defects of the entire vermilion with a buccal musculomucosal flap following resection of malignant tumors of the lower lip. *Plast. Reconstr. Surg.* 100: 422, 1997.
- Tezel, E., Numanoglu, A., Celebiler, O., and Bayramicli, M. Commissure-based buccal mucosal flap. *Plast. Reconstr. Surg.* 101: 1223, 1998.
- Mukherji, M. M. Cheek flap for short palates. *Cleft Palate J.* 6: 415, 1969.
- Jackson, I. T. Closure of secondary palatal fistulae with intra-oral tissue and bone grafting. *Br. J. Plast. Surg.* 25: 93, 1972.
- Ganguli, A. C. Surgical management of the short palate. *Trans. Int. Congress Plast. Reconstr. Surg. Butterworth* 1971: 247.
- Kaplan, E. N. Soft palate repair by elevator muscle reconstruction and a buccal mucosal flap. *Plast. Reconstr. Surg.* 56: 129, 1975.
- Maeda, K., Ojimi, H., Utsugi, R., and Ando, S. A T-shaped musculomucosal buccal flap method for cleft palate surgery. *Plast. Reconstr. Surg.* 79: 888, 1987.
- Jackson, I. T., McLennan, G., and Scheker, L. R. Primary veloplasty or primary palatoplasty: Some preliminary findings. *Plast. Reconstr. Surg.* 72: 153, 1983.
- Freedlander, E., and Jackson, I. T. The fate of buccal mucosal flaps in primary palatal repair. *Cleft Palate J.* 26: 110, 1989.
- Bozola, A. R., Gasques, J. A., Carriquiry, C. E., and Cardoso de Oliveira, M. The buccinator musculomucosal flap: Anatomic study and clinical application. *Plast. Reconstr. Surg.* 84: 250, 1989.
- Nakakita, N., Maeda, K., Ojimi, H., Utsugi, R., and Maekawa, J. The modified buccal musculomucosal flap method for cleft palate surgery. *Plast. Reconstr. Surg.* 88: 421, 1991.
- Ohishi, M., Miyanoshita, Y., Suzuki, A., and Goto, K. A revisited method of conservative palatoplasty. *J. Craniomaxillofac. Surg.* 20: 198, 1992.
- Zhao, Z., Li, S., Yan, Y., et al. New buccinator myomucosal island flap: Anatomic study and clinical application. *Plast. Reconstr. Surg.* 104: 55, 1999.
- Filiberti, A. T. Plastic closure of septal perforation. *Ann. Chir. Otorhinolaryngol. (Cordoba)* 96: 1, 1965.
- Tipton, J. B. Closure of large septal perforations with labial-buccal flap. *Plast. Reconstr. Surg.* 46: 514, 1970.
- Soutar, D. S., Elliot, D., and Rao, G. S. S. Buccal mucosal flaps in nasal reconstruction. *Br. J. Plast. Surg.* 43: 612, 1990.
- Rayner, C. R. W. Oral mucosal flaps in midfacial reconstruction. *Br. J. Plast. Surg.* 37: 43, 1984.